

Indicators of domestic violence – dentistry

Factsheet



Click [here](#) for a video on how dentists can help victims of DV.



Please note that **none or all of these indicators might be present** or may be indicators of other issues, but they can serve as warning signs and a reason for increased attention and can point towards (a history of) DV.

“Dentists are in the unique position to be the first line of defence in identifying evidence of assault, and then reporting potential cases of domestic violence”⁽¹⁾

Dentists are uniquely positioned to identify victims of domestic violence (DV) due to the extended time they spend with patients, averaging 30-60 minutes, compared to the shorter durations with primary care physicians.⁽²⁾ Through routine check-ups and multi-session therapies, dentists develop a deeper understanding of their patients, enabling them to detect behavioral changes.⁽³⁾ Importantly, many victims of domestic violence, particularly those with injuries to the head, neck, or face, are more likely to keep dental appointments, providing dentists with crucial opportunities for observation.⁽⁴⁾

Studies indicate that injuries in these areas, occurring in 40-75% of cases, often reveal the extent of abuse. Notably, a woman seeking treatment for facial injuries has a one in three chance of being a victim of domestic violence.^{(5) (6)}

Injuries of the head-neck-face region are considered a significant indicator of DV. Odontologists dentists, and maxillofacial surgeons should be able to recognise maxillofacial trauma in the head and neck region as a possible indicator of DV.

Please note that the lists are not exhaustive; it represents only a selection.

Possible indicators in the neck-face area⁽⁷⁾

- **Slow Head:** Bumps, patchy hair loss, bruises on forehead
- **Fractures on the front of the skull:** Often the result of direct trauma.
- **Eyes:** Monocle haematoma (periocular haematoma), intraocular haemorrhage, orbital fractures, petechiae.
- **Earlobes:** Bruise marks, haematoma.
- **Neck:** Strangulation marks, bite wounds, petechiae.
- **Psychological:** Fear of fast movements, fear of pain, fear of "being at the mercy" of the dentist.





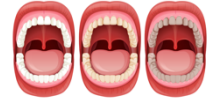Individuals from **diverse cultural backgrounds may manifest their symptoms differently.**

Please remain conscious of your own **perspective, biases, and stereotypes** when communicating with a potential victim, as these factors can impact how you assess the symptoms. Find more information in [Modul 8](#).

A facial trauma includes

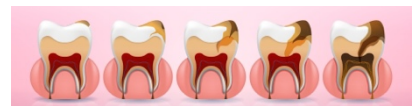
- Facial soft tissue injuries e.g. grazes, bruises, abrasions, cuts, scratches, haematomas, burns and lacerated contusion wounds.
- Maxillofacial fractures associated with DV may include pain, swelling, hematoma, bleeding, deformity of the face, difficulty breathing or speaking, and loss of sensation or vision.
- Traumatic bone injuries: fractures of the nose, zygomatic bone, upper and lower jaw and eye socket.

Possible indicators in the mouth and tooth area ⁽⁸⁾⁽⁹⁾



- Traumatic fractures (e.g. upper and lower jaw, cheekbone or nose)
- Dislocations and injuries to the jaw joint
- Signs of previous trauma to the dental or orofacial structures (e.g. healed fractures on X-ray)
- Broken, subluxated or knocked out teeth
- Poor dental status, neglected dental hygiene, failure to attend preventive check-ups
- Rupture of the upper lip frenulum, injuries to the lips, haematoma on the dental ridges or facial tissue
- Halitosis, dry mouth, inflammation of the tongue, mouth corner rhagades
- Bruises or abrasions of the soft or hard palate due to sexual abuse (penetration) ⁽¹⁰⁾, excessive gag reflex or none at all
- Higher risk of periodontitis and gingivitis (due to e.g. stress) ⁽¹¹⁾
- Tooth enamel erosion due to bulimia and prolonged sperm retention in the mouth
- Signs of sexually transmitted diseases in the oral mucosa e.g. syphilis, acute HIV, herpes, papilloma or Candida infections ⁽¹²⁾
- Petechial congestive haemorrhages in oral mucosa as indicator for strangulation

Dental neglect



Dental neglect frequently leads to a persistent state of untreated carious lesions. There is no specific threshold value that defines dental neglect based on the number of carious lesions. However, it is established that in the permanent dentition of neglected children, **untreated carious lesions occur at a frequency eight times higher** than in non-neglected children.

Refusing necessary treatment, support with oral hygiene, or missing dentist appointments despite awareness of the child's dental needs is a significant sign of neglect.



Find more information on general **indicators** in [Module 2](#).

Possible indicators for abuse and neglect of children⁽¹³⁾⁽¹⁴⁾

Abuse and neglect are both forms of domestic violence, but they differ from each other.

Form of DV	Abuse	Neglect*
Physical	Violent, non-accidental injuries	Inadequate care and/or health care over a longer period of time (e.g. "dental neglect"), malnutrition, inadequate personal hygiene, inappropriate clothing.
Emotional	Psychological damage due to excessive demands, threats, triggering of fears and feelings of inferiority ("I wish you weren't born")	Persistent and repeated disregard of the child's emotional needs, deprivation of care, love and security.
Sexual	Active and passive involvement of the child in sexual acts	

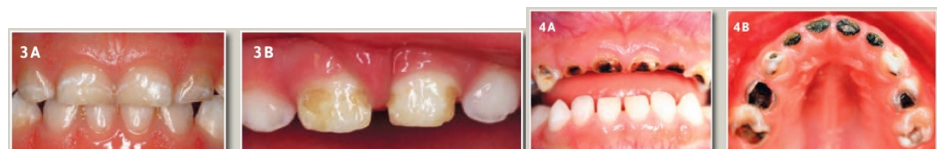* The neglecting person (persons with custody and those with a duty of care) is always identifiable

Early Childhood Caries (EEC)

"Teat bottle caries" as a manifestation of child neglect⁽¹⁵⁾:

- Carious milk tooth disease, which occurs after the eruption of the first milk teeth until the beginning of the change of teeth at the latest (6th year of life). Cause: Sugary drinks given via feeding bottles combined with inadequate dental care.

Wyne categorises dental neglect into three severity levels. **Type 1** denotes **mild to moderate** neglect, characterised by isolated carious lesions on milk molars and incisors. **Type 2** represents **moderate to severe** neglect, featuring carious lesions on the palatal surfaces of upper deciduous incisors, with lower teeth remaining caries-free; the involvement of deciduous molars depends on age. **Type 3** signifies **severe** neglect, evidenced by carious lesions on almost all deciduous teeth, including the lower incisors, and extends to areas typically resistant to caries.



Images with kind permission, PD Dr J. Schmoeckel

Helpful sources

They can be found [here](#).

- (1) Dentistry responding in domestic violence and abuse (DRiDVA) feasibility study: a qualitative evaluation of the implementation experiences of dental professionals, p. 5
- (2) Enhancing dental professionals' response to domestic Violence, National health resource center on domestic violence, San Francisco.
- (3) Perception of women with lived experience of domestic violence and abuse on the involvement of the dental team in supporting adult patients with lived experience of domestic abuse in England: a pilot study, p. 6
- (4) RCFV Full Report Interactive – The role of the health system (p. 24) – Royal Australian and New Zealand College of Psychiatrists, Submission 395
- (5) Denistry responding in domestic violence and abuse (DRiDVA) feasibility study: a qualitative evaluation of the implementation experiences of dental professionals, p. 2
- (6) Wu V, Huff H, Bhandari M. "Pattern of Physical Injury Associated with Intimate Partner Violence in Women Presenting to the Emergency Department: A Systematic Review and Meta-Analysis". *Trauma Violence Abuse* 2010, 11(2):71–82.
- (7) Sujatha, G., Sivakumar, G., & Saraswathi, T. R. (2010). Role of a dentist in discrimination of abuse from accident. *Journal of forensic dental sciences*, 2(1), 2–4. <https://doi.org/10.4103/0974-2948.71049>
- (8) Moore, Roisin & Newton, Jonathon. (2012). The role of the general dental practitioner (GDP) in the management of abuse of vulnerable adults. *Dental update*. 39. 555-6, 558. 10.12968/denu.2012.39.8.555.
- (9) Family violence handbook for the dental community, Donna Denham and Joan Gillespie, 1994, Health Canada
<https://publications.gc.ca/collections/Collection/H72-21-136-1995E.pdf>
- (10) Recognize the signs of domestic violence,
<https://decisionsindentistry.com/article/recognize-the-signs-of-domestic-violence/>, accessed 15 November 2023.
- (11) Minhas S, Qian Hui Lim R, Raindi D, Gokhale KM, Taylor J, Bradbury-Jones C, Bandyopadhyay S, Nirantharakumar K, Adderley NJ, Chandan JS. Exposure to domestic abuse and the subsequent risk of developing periodontal disease. *Heliyon*. 2022 Dec 23;8(12):e12631. doi: 10.1016/j.heliyon.2022.e12631, p. 2.
<https://www.springermedizin.de/sexuell-uebertragbare-infektionen-der-mundhoehle/8026832>
- (12) <https://viamedici.thieme.de/lernmodul/8678896/5446192/kindesmisshandlung+und+vernachlaessigung>, accessed 16. November 2023
- (13) https://www.kinderschutz-in-nrw.de/fileadmin/user_upload/Materialien/Pdf-Dateien/Kindesvernachlaessigung_2019_Web.pdf, p. 15.
- (14) Hartung, B., Schaper, J., Fischer, K., Ritz-Timme, S.: Care for children with dental neglect: identification of problems and approaches to solving them. *International Journal of Legal Medicine*; 133 (2): 641-650. DOI:10.1007/s00414-018-1938-x. Epub 2018 (Sep.2019)

Images

- (1) Face: Image by [Freepik](#)
- (2) Mouth: Image by [brgfx](#) on [Freepik](#).
- (3) Teeth: [Caries Vectors](#) by Vecteezy
- (4) EEC: Images with kind permission, [PD Dr J. Schmoeckel](#)